

# PEDIATRICS®

## **Iatrogenic Harm Caused by Diagnostic Errors in Fibrodysplasia Ossificans Progressiva**

Joseph A. Kitterman, Sharon Kantanie, David M. Rocke and Frederick S. Kaplan

*Pediatrics* published online Oct 17, 2005;

DOI: 10.1542/peds.2005-0469

**This information is current as of October 24, 2005**

The online version of this article, along with updated information and services, is  
located on the World Wide Web at:

<http://www.pediatrics.org/cgi/content/full/peds.2005-0469v1>

PEDIATRICS is the official journal of the American Academy of Pediatrics. A monthly publication, it has been published continuously since 1948. PEDIATRICS is owned, published, and trademarked by the American Academy of Pediatrics, 141 Northwest Point Boulevard, Elk Grove Village, Illinois, 60007. Copyright © 2005 by the American Academy of Pediatrics. All rights reserved. Print ISSN: 0031-4005. Online ISSN: 1098-4275.

American Academy of Pediatrics

DEDICATED TO THE HEALTH OF ALL CHILDREN™



# Iatrogenic Harm Caused by Diagnostic Errors in Fibrodysplasia Ossificans Progressiva

Joseph A. Kitterman, MD\*; Sharon Kantanie, MAT‡; David M. Rocke, PhD§; and Frederick S. Kaplan, MD||

**ABSTRACT.** *Background.* Little is known about diagnostic errors for a disease worldwide. Such errors could alter the disease's natural history, especially if unwarranted interventions cause irreversible harm. Fibrodysplasia ossificans progressiva (FOP), a rare, autosomal dominant genetic disease characterized by episodes of permanent heterotopic ossification of soft tissues, occurs worldwide without racial, ethnic, or geographic predilection. There is no effective treatment, and soft-tissue trauma (eg, biopsies, surgical procedures, intramuscular injections, or mandibular blocks for dental procedures) and viral illnesses are likely to induce episodes of rapidly progressive heterotopic ossification, with resultant permanent loss of motion in the affected area. Accurate diagnoses can be made on the basis of the clinical findings of tumor-like swellings on the head, neck, back, or shoulders and characteristic short great toes with hallux valgus-like malformations and missing interphalangeal joints. On the basis of conversations with numerous individuals with FOP, we suspected that diagnostic errors with FOP are common and often associated with inappropriate and harmful diagnostic and therapeutic procedures.

*Objective.* To document the frequency of diagnostic errors with FOP and complications resulting from misdiagnoses.

*Design.* A questionnaire requesting detailed demographic, diagnostic, and treatment information was sent to all 269 patient-members of the International FOP Association; the sampling frame included >90% of all known FOP patients worldwide. We received 138 replies (51% response) from 25 countries. The age range was 2 to 71 years; there were 78 female subjects and 60 male subjects. In addition, to assess the availability and adequacy of information about FOP, we reviewed 184 En-

glish-language textbooks in relevant specialties published in the past 20 years.

*Results.* Incorrect diagnoses were given initially to 87% of individuals with FOP. This astonishing rate of diagnostic errors occurred worldwide, regardless of ethnicity, geographic background, or misdiagnosing physician's specialty. The most common incorrect diagnosis was cancer (32%). The mean period from the onset of symptoms to correct diagnosis was 4.1 years, and the median number of physicians consulted before the correct diagnosis of FOP was 6. For 67% of patients, unnecessary invasive procedures (biopsies) were performed; 68% received inappropriate therapies. Forty-nine percent of all patients reported permanent loss of mobility resulting from invasive medical interventions that caused posttraumatic ossification. Notably, only 8% of the 184 textbooks that were reviewed contained adequate descriptions of FOP, including the caution that trauma can accelerate the process of heterotopic ossification.

*Conclusions.* Diagnostic errors and inappropriate medical procedures, which may lead to permanent harm, can alter the natural history of a disease. In FOP, the astonishing rates of diagnostic errors and inappropriate invasive medical procedures likely result from lack of physician awareness because of failure of information transfer. *Pediatrics* 2005;116:e654-e661. URL: [www.pediatrics.org/cgi/doi/10.1542/peds.2005-0469](http://www.pediatrics.org/cgi/doi/10.1542/peds.2005-0469); *cancer, fibromatosis, heterotopic ossification, medical errors, myositis ossificans.*

---

ABBREVIATIONS. BMP4, bone morphogenetic protein 4; FOP, fibrodysplasia ossificans progressiva; IFOPA, International Fibrodysplasia Ossificans Progressiva Association; UCSF, University of California, San Francisco.

---

From the \*Department of Pediatrics and Cardiovascular Research Institute, University of California San Francisco, San Francisco, California; †International Fibrodysplasia Ossificans Progressiva Association, Winter Springs, Florida; ‡Department of Applied Science, Division of Biostatistics, University of California Davis, Davis, California; and ||Departments of Orthopedic Surgery and Medicine, University of Pennsylvania School of Medicine, Philadelphia, Pennsylvania.

Drs Kitterman and Kaplan conceived and designed the study. Dr Kitterman and Ms Kantanie participated in collection and compilation of the data. Drs Kitterman, Rocke, and Kaplan participated in analysis and interpretation of the data and in writing of the manuscript. All authors have seen and approved the final version.

Accepted for publication Jun 28, 2005.

doi:10.1542/peds.2005-0469

The questionnaire used in this study is available from the corresponding author.

No conflict of interest declared.

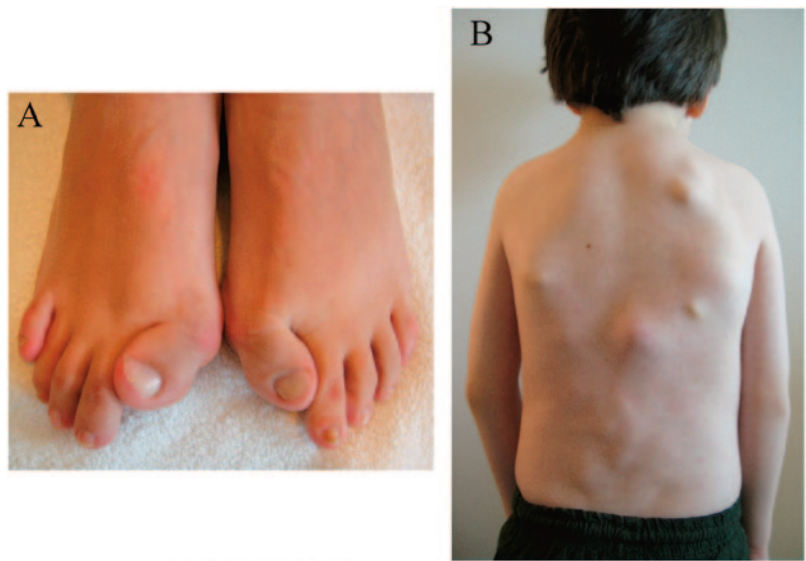
Reprint requests to (J.A.K.) Department of Pediatrics, Box 0734, University of California, San Francisco, San Francisco, CA 94143. E-mail: [kittermj@peds.ucsf.edu](mailto:kittermj@peds.ucsf.edu)

PEDIATRICS (ISSN 0031 4005). Copyright © 2005 by the American Academy of Pediatrics.

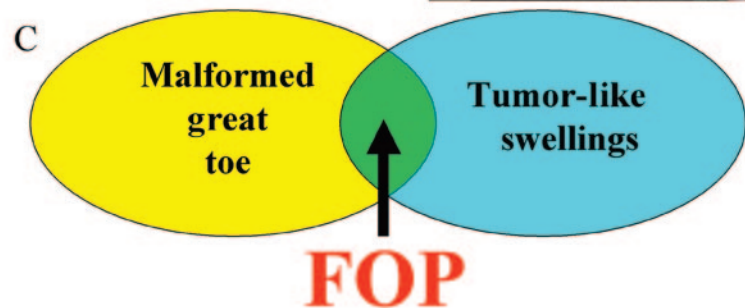
The accurate diagnosis of disease has been a basic principle of medical care since antiquity. Mistaken or delayed diagnosis can lead to morbidity or death through use of inappropriate procedures or through withholding of necessary treatments. Rates of diagnostic errors for common diseases, such as acute cardiac ischemia, tend to be low,<sup>1,2</sup> but relatively little is known about the unnatural history of rarer disorders in which iatrogenic harm resulting from misdiagnosis may be common.

Fibrodysplasia ossificans progressiva (FOP) is a rare genetic disorder with autosomal dominant inheritance<sup>3,4</sup> and a point prevalence of ~1 case per 2 million population worldwide.<sup>5</sup> Almost all individuals with FOP have congenital malformations of the great toes that are recognizable at birth, consisting of a hypoplastic proximal phalanx with associated hallux valgus<sup>6</sup> (Fig 1A).

FOP is characterized postnatally by episodes of



**Fig 1.** A shows a photograph of the feet of a 5-year-old boy with FOP, showing the characteristic findings of short great toes and hallux valgus; B, photograph of the back of the same child, with tumor-like swellings on his back and right shoulder that represent early FOP flare-ups; C, diagram of differential diagnoses for malformations of the great toes and tumor-like swellings, demonstrating that, when both are present, the diagnosis is FOP.



Differential diagnosis:

- |                                     |                                    |
|-------------------------------------|------------------------------------|
| • Isolated Congenital Malformations | • Sarcoma, Lymphoma                |
| • Brachydactyly (isolated)          | • Desmoid Tumor                    |
| • Juvenile bunions                  | • Aggressive Juvenile Fibromatosis |

progressive ossification of soft tissues, with permanent loss of mobility.<sup>7,8</sup> Symptoms begin during early childhood and include tender swellings on the head, neck, or back. Although ossification may not be evident early in the course, these swellings most often progress to ossification (Fig 1B). Recognition of the characteristic great toe malformations, in association with the usual symptoms of rapidly changing swellings on the head, neck, or back, allows accurate clinical diagnosis of FOP. Although there is no effective treatment, it is important to avoid soft-tissue trauma, including biopsies,<sup>7</sup> intramuscular injections,<sup>9</sup> surgical procedures,<sup>7,10</sup> and mandibular blocks for dental procedures,<sup>11</sup> as well as viral illnesses.<sup>12</sup> All of these are likely to induce episodes of rapidly progressive heterotopic ossification, with resultant permanent loss of motion in the affected area. Therefore, trauma prevention is a major aspect of care, and the cost to the patient of misdiagnosis and inappropriate intervention is high.

Diagnostic delays occur while investigative procedures are undertaken for many diseases, and patients suffer no lasting harm with most disorders. With FOP, however, minor soft-tissue trauma induces and accelerates disabling permanent hetero-

topic ossification. Attempts to remove heterotopic bone from patients with FOP lead rapidly to massive new bone formation.<sup>8</sup> During discussions with individuals with FOP and their family members, from many countries, at the Third International FOP Symposium in November 2000, we were impressed with the prevalence of patients with FOP who described erroneous initial diagnoses. Also, patients often reported invasive diagnostic procedures and treatments that were associated with worsening of the patient's condition, hastened progression of FOP and its disabling effects, and caused delays in finding needed resources. Although a search of the PubMed database (of the National Library of Medicine) for FOP yielded 584 references from the past 20 years, of which 204 referred directly to FOP, a cursory review of medical textbooks revealed that few mentioned FOP or described its clinical features.

To determine the frequency of problems associated with diagnostic errors and inappropriate interventions among patients with FOP, we sent a questionnaire to all members of the International FOP Association (IFOPA), asking about their experiences. This report describes the results of that survey. As expected, diagnostic errors were common among pa-

tients with FOP who responded to the survey, and approximately one half of the patients considered that they suffered permanent sequelae because of the diagnostic errors.

## METHODS

### Questionnaire

We prepared a questionnaire about each individual's experience with the diagnosis and treatment of FOP. The questionnaire requested detailed demographic, diagnostic, and treatment information about each individual with FOP.

### Patient Recruitment

Addresses (both postal and e-mail) of all patient-members were obtained from the IFOPA, an international association of 269 self-enrolled patient-members with FOP from 28 countries and 6 continents. These patients represented >90% of the known cases of FOP worldwide. FOP was verified for all patients through previous examination by one of the authors (F.S.K.), examination by another physician knowledgeable about FOP, or through review of the history, relevant photographs, and radiographs. The questionnaire was sent via e-mail or postal mail to all patient-members of the IFOPA; the questionnaire was also posted on the IFOPA Web site ([www.ifopa.org](http://www.ifopa.org)) in English, French, and Spanish. A consent form was included with the questionnaire. The survey was posted on the IFOPA Web site in September 2001, and questionnaires were mailed during the following several weeks. For individuals with FOP who were minors, we requested that the parents or guardians obtain the assent of the child with FOP and then complete and return the questionnaire. The last response was received in November 2002. The research project was approved by the Committee on Human Research of the University of California, San Francisco (UCSF). Patient confidentiality was ensured in public reporting of all results, in accordance with standards set by the UCSF Committee on Human Research.

### Textbook Survey

We reviewed English-language textbooks of clinical genetics, internal medicine, metabolic bone disease, neonatology, oncology, pediatrics, pediatric oncology, orthopedic surgery, and pediatric orthopedics, in the Kalmanovitz Medical Library at UCSF, that were published in the past 20 years. Because of the malformations of the great toes among individuals with FOP, we also reviewed textbooks of podiatry in the Graziano Library of the California School of Podiatric Medicine (Oakland, CA). The index of each textbook was searched for the following terms: fibrodysplasia ossificans progressiva, myositis ossificans progressiva, Muenchmeyer's syndrome, and myositis ossificans. When any of these was listed, the text was examined to determine whether it described the features of FOP, mentioned the typical malformations of the great toes, and cautioned against invasive procedures (either diagnostic or therapeutic).

### Data Analysis

Results were compared between responses from the United States and those from other countries. Continuous variables were compared by single-factor analysis of variance. Noncontinuous variables were compared with the  $\chi^2$  test. All data analyses were performed with Microsoft Excel software (Microsoft, Redmond, WA). Significance was assumed for *P* values of <.05.

## RESULTS

### Patients

We sent questionnaires to the 269 patient-members of the IFOPA and received completed questionnaires from 138 individuals with FOP (51% response) from 5 continents. There were 64 replies from 27 states in the United States and 74 replies from 24 other countries. Fifty-one questionnaires were completed by individuals with FOP, 80 by parents of those with FOP, and 7 by others. The median age of individuals with FOP was 21 years (range: 2–71 years); 78 were

female and 60 were male. Of the 138 responses, 131 (95%) stated that the patients had typical congenital malformations of the great toes (Fig 1A). Although the malformed great toes had been noted at birth by a caregiver or family member for 101 individuals (73%), FOP was diagnosed before 6 months of age for only 4 individuals (3%).

### Symptoms

The median age of onset of symptoms of FOP was 2.5 years (range: birth to 17 years). The most common presenting symptoms were tumor-like swellings, stiffness, and abnormal bone formation after mild trauma (Table 1). For 13 individuals (9%), symptoms were noted in the neonatal period, including 7 patients with tumor-like swellings on the head or back, 3 with stiffness of the neck, and 1 each with stiffness of the hips, bone formation at the site of a scalp laceration during cesarean section, and a very large callus at a clavicular fracture site.

### Errors and Delays in Diagnosis

Erroneous diagnoses were remarkably frequent. FOP was the initial diagnosis for only 18 individuals (13%). Many patients were given >1 incorrect diagnosis, and the more commonly ascribed incorrect diagnoses are listed in Table 2. Diagnoses of cancer or fibromatosis, including aggressive juvenile fibromatosis and desmoid tumor, were given to 51 patients (37%). Delays between the onset of symptoms and the correct diagnosis of FOP were frequent. The median age at diagnosis of FOP was 5.7 years (range: 1 week to 56 years). The mean delay from the onset of symptoms to diagnosis was  $4.1 \pm 7.9$  years (mean  $\pm$  SD; median: 1.1 year; range: <1 month to 49 years). The delay in diagnosis was  $\geq 1$  year for 80 individuals and  $\geq 2$  years for 56 individuals.

Individuals consulted a wide variety of generalists and specialists. Those consulted most frequently were orthopedic surgeons (consulted by 89 individuals), pediatricians (consulted by 88 individuals), general practitioners (consulted by 71 individuals), oncologists (consulted by 43 individuals), rheumatologists (consulted by 28 individuals), and internists (consulted by 19 individuals). Before the correct diagnosis of FOP, the median number of doctors consulted was 6 (range: 1–51 physicians), and the patients were referred to a wide range of medical

TABLE 1. Presenting Symptoms for 138 Patients With FOP

Initial Symptom Noted	No. of Patients (%) (N = 138)
Swellings or tumors	91 (66)
On head, neck, or back	77
On shoulders	7
Elsewhere	7
Stiffness	35 (25)
Of neck or back	27
Elsewhere	8
Bone formation after trauma*	17 (12)
Other (pain, limp, or fever)	5 (4)

The total number presented is greater than 138 because some individuals described >1 presenting symptom.

\* Trauma includes immunizations.



**TABLE 2.** Frequency of the More Common Incorrect Diagnoses Given to 138 Patients With FOP

Diagnosis	No. Given the Diagnosis
Cancer	32
Fibromatosis*	19
Bunions (or hallux valgus)	9
Injuries attributable to trauma or overuse	7
Myositis (including myositis ossificans)	6
Calcified hematoma	6
Arthritis (including rheumatoid arthritis)	5
Craniofasciitis	4
Exostoses	4
Ankylosing spondylitis	3
Neurofibromatosis	3
Poliomyelitis	3
Scleroderma	3

Thirty-four other diagnoses were given to 1 or 2 patients each.

\* Including aggressive fibromatosis and desmoid tumors.

facilities, including cancer hospitals, children's hospitals, orthopedic hospitals, and university medical centers. The correct diagnosis of FOP was made by physicians in a wide range of specialties; 34 cases were diagnosed by orthopedic surgeons, 20 by pediatricians, 16 by geneticists, 14 by rheumatologists, 11 by oncologists, 9 by radiologists, 3 by internists, 3 by neurologists, 2 by emergency medicine specialists, 2 by nephrologists, and 1 each by a dermatologist, a general surgeon, a neurosurgeon, an otolaryngologist, a pathologist, and a genetic counselor. In 18 cases, the physician's specialty was not specified. FOP was first suggested as the diagnosis by a parent in 3 cases and by the individual with FOP in 1 case (after watching a television documentary about FOP and then searching the Internet).

### Diagnostic Interventions

All except 2 patients (98%) reported that they had undergone some type of diagnostic testing, including radiographs for 117 patients, blood tests for 105, computed tomographic scans for 63, MRI scans for 19, bone scans for 10, and ultrasonographic scans for 6. Biopsies of lesions were performed for 92 patients (67%). Open surgical biopsies were performed for 56 patients (41%), closed needle biopsies for 12 (9%),

and both types of biopsies for 24 (17%). Multiple biopsies (2–7 biopsies) were performed for 37 individuals (27%).

### Therapeutic Interventions

Ninety-four patients (68%) received  $\geq 1$  therapeutic intervention, including physiotherapy for 39 patients, chemotherapy for 14, and radiotherapy for 7. Surgical removal of the abnormal mass or tumor was performed for 36 patients (26%); multiple surgical procedures (2–6 procedures) were performed for 11 individuals. As a result of 2 biopsies that led to an erroneous diagnosis of cancer, 1 individual underwent a forequarter amputation at 3 years of age. For 26 individuals (19%), a surgical procedure was performed on the great toes in an attempt to correct the toe malformations; 4 of these individuals underwent multiple surgical procedures on their toes. Nonsurgical treatments of the abnormal toes were given to 23 patients and included casting, splinting, orthotic inserts, and special shoes. All of the aforementioned diagnostic and therapeutic interventions are inappropriate treatments for individuals with FOP.

### Complications Resulting From Medical Interventions

Seventy-one patients (51%) reported side effects of diagnostic or therapeutic interventions. For 4 patients, the side effects were temporary (eg, obesity resulting from steroid therapy or illness resulting from chemotherapy). For the other 67 patients (49%), however, side effects led to permanent complications (Table 3). For all except 1 patient, the complication was permanent loss of movement attributable to exacerbation of heterotopic bone formation caused by the traumatic interventions. The other individual underwent a forequarter amputation. Permanent complications occurred for 32 (35%) of the 92 patients who received biopsies and 37 (60%) of the 62 patients who underwent surgical procedures. Inappropriate dental procedures (mandibular blocks or stretching of the temporomandibular joint) caused serious loss of motion of the jaw for 14 patients. Inappropriate invasive procedures were performed for 34 patients (25%) after they had been diagnosed with FOP (Table 3).

**TABLE 3.** Diagnostic and Therapeutic Interventions and Permanent Complications for 138 Patients With FOP

Type of Intervention	No. (%)		
	Intervention	Intervention Performed After Diagnosis of FOP	Permanent Complications*
Biopsy	92 (67)†	4	32 (35)‡
Surgical procedure	48 (35)†	10	29 (60)‡
Removal of mass	31		24
Operation on toes	26		4
Amputation	1		1
Dental procedure	NA	12	14
Intramuscular injection§	NA	8	12
Physiotherapy	39 (28)†		6 (15)‡

NA indicates information not available.

\* Permanent complications occurred for 67 patients. This column totals  $>67$  because some patients reported permanent complications resulting from  $>1$  intervention.

† Percentage of all patients who responded to the questionnaire.

‡ Percentage of patients receiving the intervention who suffered a permanent complication.

§ Including immunizations.

Twenty-six patients associated invasive interventions with profound complications. The amputation of an arm and shoulder of a small child is an extreme example of harmful inappropriate therapy. Comments by several patients or parents indicated the severity of permanent complications; examples included the following. Commenting on surgical removal of heterotopic bone in his shoulder at 12 years of age, a young man wrote, "I could not move my arm after that." Describing effects of biopsies on his 6-year-old daughter, a father wrote, "The 2 surgical biopsies accelerated the growth of bone in her neck, shoulder, and back." Referring to her young son, who underwent 5 operations to remove heterotopic bone, a mother wrote, "After each operation, there was more loss of movement and more lumps, but each specialist insisted on removing more." Describing the effects of an intramuscular immunization and physical therapy on her 3-year-old son, a mother stated, "His leg is now rigid and curves the opposite of the way the knee bends." Another mother's description of the aftereffects of an operation to straighten her daughter's thumbs and toes included, "After the operation, the fingers and toes remained rigid." A young woman described the effects of inappropriate dental work, "Extractions of teeth led to fusing of my jaw." Describing the effects of surgery to remove heterotopic bone from her shoulder, a woman stated, "After the surgery, the neck and shoulders became more rigid, the elbows contracted, and the spine became completely rigid."

#### Advice Given to Patients

Of the 138 responses, 121 (88%) stated that the patients were given advice regarding the prognosis for FOP. The advice was accurate in only 64 cases (53%). Little or no information regarding prognosis was given to 21 patients (17%), and inaccurate information was given to 36 (30%). In most of those cases, the parents were told erroneously that their child would die soon. In other cases, the parents were informed incorrectly that FOP would "burn out" at a certain age. After the diagnosis of FOP had been made, the parents or the individual with FOP took responsibility to inform their previous doctors about the diagnosis of FOP in 32 cases (23%).

There were no significant differences between patients in the United States and those in other countries for any of the variables examined. There are several possible reasons for this. First, there were not many patients from any one other country, or even from continents such as Europe, to allow much statistical power to detect differences. Grouping all non-United States patients together may mask possible differences because of heterogeneity in the non-United States group but is necessary to avoid this severe loss of power. Even with this crude classification, differences would be difficult to detect. For example, if a response were 40% in the United States and 60% outside the United States, with the sample sizes available there would be only 45% power to detect the effect at the 5% level with the  $\chi^2$  test.

#### FOP in Medical Textbooks

In an effort to ascertain why accurate diagnosis of FOP was so often delayed and why so many patients received inappropriate and harmful interventions, we reviewed 184 English-language textbooks published in the past 20 years in a variety of medical fields (Table 4). The aim was to determine whether FOP was described adequately and accurately in textbooks. The clinical features of FOP, including the malformations of the great toes, were described in 61% of textbooks of metabolic bone diseases and 56% of textbooks of clinical genetics, but cautions about the complications of trauma were included in only 38% and 25%, respectively. FOP was described, with descriptions of the toe malformations, in 23% of textbooks of orthopedics and pediatric orthopedics. In contrast, FOP was rarely described or even mentioned in textbooks of internal medicine, oncology, pediatric oncology, pediatrics, neonatology, or podiatry. A major concern is that only 8% of the 184 textbooks examined cautioned that trauma is likely to cause exacerbations of the heterotopic ossification and to lead to severe permanent loss of function.

#### DISCUSSION

The results of this study indicate that, for the 138 individuals with FOP who responded to the questionnaire, erroneous diagnoses were astonishingly frequent and were commonly associated with appar-

**TABLE 4.** Summary of Findings Regarding FOP in 184 Medical and Podiatric Textbooks

Type of Textbook	No. Reviewed	No. (%) of Textbooks That			
		Mentioned FOP	Described FOP Features	Described Malformed Great Toes	Cautioned About Risks of Trauma
Metabolic bone disease	13	8 (61)	8	8	5
Genetics	16*	9 (56)	9	7	4
Orthopedics	35	12 (34)	8	7	1
Pediatric orthopedics	13	4 (31)	3	3	0
Podiatry	18	4 (22)	3	3	0
Pediatrics	30	5 (17)	4	3	0
Oncology	18	3 (16)	3	2	2
Internal medicine	19†	3 (16)	3	3	2
Pediatric oncology	14	1 (7)	1	1	1
Neonatology	8	0	0	0	0
Total	184	49 (27)	42 (23)	37 (20)	15 (8)

\* Including 1 online medical information Web site.

† Including 2 online medical information Web sites.

ent iatrogenic harm. These individuals represent ~50% of the cases of FOP worldwide that were known at the time of the study. The response rate of 51% is greater than is usual for mail surveys, most likely because of strong motivation in the FOP community. The vast majority of those who responded (87%) initially received erroneous diagnoses, 67% underwent invasive diagnostic procedures (surgical or needle biopsies), 54% were subjected to invasive or potentially harmful therapeutic interventions (surgery, chemotherapy, or physical therapy), and 49% reported serious permanent complications resulting from inappropriate interventions. These errors in diagnosis and management occurred among both hospitalized patients and outpatients, in a wide variety of medical settings. It is not possible to exclude bias in many of the conclusions, and it could be that those who responded to the survey represented patients with prolonged delays in diagnosis or unusually severe complications resulting from medical interventions. However, even if the 131 individuals with FOP who did not respond to the questionnaire were accurately diagnosed initially and were not subjected to harmful interventions, there would still be a 45% rate of erroneous diagnoses, with 25% of the entire group reporting permanent complications resulting from medical interventions.

The clinical presentation of tender masses in FOP, before the appearance of heterotopic ossification, has led many physicians to consider neoplasm as the underlying cause. Cancer and other tumors were the most common initial diagnoses in the current study (Table 2), a major factor in the high percentage (67%) of patients who were subjected to biopsy. However, most neoplasms tend to grow in a slowly progressive and accelerating manner. In contrast, lesions of FOP appear suddenly and change size and shape rapidly, often in a matter of hours; their rate of change is far greater than that seen for most tumors.

The subject of medical errors has received much attention since publication of the Institute of Medicine report in 2000.<sup>13</sup> Although that report and most subsequent publications were directed toward decreasing or eliminating errors among hospitalized patients,<sup>14</sup> it has been well documented that errors also occur in settings outside the hospital. In an Australian study of outpatients, errors were common and frequently (25%) resulted in disability or death.<sup>15</sup> Furthermore, despite differences in methods, large retrospective studies in Australia<sup>16</sup> and the United States<sup>17</sup> found that serious errors occurred at similar rates in the 2 countries.<sup>18</sup> Our results are similar, in that we found no differences for patients in the United States, compared with those in other countries, with respect to frequency of erroneous diagnoses, rates of invasive diagnostic or therapeutic interventions, or duration of delay between the onset of symptoms and the correct diagnosis of FOP.

For patients with FOP, diagnostic and therapeutic errors of management resulted from initial failure to diagnose the patient's condition accurately. In several reports, delays in correct diagnosis were identified as major causes of medical errors,<sup>14,15,19–21</sup> leading frequently to permanent disability. It is well

known that, when physicians are experienced in treating a condition, results are better for both medical<sup>22,23</sup> and surgical<sup>24</sup> treatments. Similarly, diagnostic errors are relatively rare for common diseases, eg, ~2% for acute cardiac ischemia.<sup>1,2</sup> With less common diseases, however, incorrect diagnoses become more common. Parkinson's disease, with a prevalence of 1.8 case per 100 individuals >65 years of age,<sup>25</sup> has an initial diagnostic error rate of ~20%.<sup>26</sup> Wilson's disease, a rare condition with an incidence of 12 to 29 cases per 1 million population, has a high rate of diagnostic failure, ie, ~60%.<sup>27,28</sup> For both Parkinson's disease and Wilson's disease, a possible explanation for the high rates of misdiagnoses is that manifestations of the diseases may vary markedly among different patients, making the clinical diagnosis difficult. In contrast, FOP, which is 25 to 60 times more rare than Wilson's disease, has a typical presentation of rapidly changing, tender masses on the head, neck, or shoulders for an individual with the classic malformations of the great toes (Fig 1C). This combination of findings is unique to FOP and should allow accurate, quick, clinical diagnosis without unnecessary laboratory tests; however, 87% of FOP patients who responded to the questionnaire received erroneous diagnoses initially.

The large number of physicians (median: 6 physicians) consulted before a patient received the correct diagnosis of FOP is indicative of a lack of awareness and knowledge regarding FOP among physicians. Several patients remarked on this fact in their comments in the questionnaire. A potential factor contributing to ignorance regarding FOP among physicians is a lack of information about FOP in medical textbooks. The specialties most likely to be consulted when symptoms of FOP first present are neonatology (great toe malformations are present at birth and 9% of patients experienced characteristic soft-tissue swellings of FOP in the neonatal period), pediatrics (the median age of onset of symptoms was 2.5 years and the median age at diagnosis was 5.7 years), oncology (37% received an initial diagnosis of cancer or other tumor), general practice, and internal medicine (physicians consulted by 57% of patients before the correct diagnosis of FOP). Therefore, it is a major concern that textbooks of neonatology, pediatrics, oncology (both pediatric and adult), and internal medicine rarely described or even mentioned FOP (Table 4). FOP was mentioned in 34% of textbooks of orthopedics and 61% of textbooks of metabolic bone disease (Table 4). It is notable that orthopedic surgeons were the specialists consulted most commonly (64%) by patients with FOP and the ones who made the correct diagnosis of FOP most frequently (25% of cases). Information technology has been cited as an effective method of reducing the frequency of errors in medicine.<sup>29</sup> It seems likely that improved rates of accurate diagnosis would result from more effective dissemination of information about FOP, including more extensive coverage in textbooks, more attention to the disease in undergraduate and graduate medical education, and increased awareness of FOP among those outside the medical community.

In addition to the high rate of erroneous diagnoses,



it is of great concern that 34 patients (25%) were subjected to invasive or potentially harmful procedures after they had been diagnosed as having FOP. We do not have an explanation for such actions. One possible reason is that only 8% of the 184 textbooks we reviewed provided the caution that trauma is likely to exacerbate FOP.

Recent research has elucidated some cellular, biochemical, and molecular abnormalities associated with FOP. The proliferative lesions of FOP exhibit marked increases in mast cells, compared with normal tissue or other inflammatory processes.<sup>30</sup> Stromal cells from early FOP lesions express lineage markers of smooth muscle cells, which suggests a vascular origin, and they also express an osteogenic transcription factor, bone morphogenetic protein 4 (BMP4), which suggests osteoblastic differentiation potential.<sup>31,32</sup> In addition, there is profound dysregulation of the signaling pathway for BMP4 in FOP cells.<sup>33</sup> Lymphoblastoid cells from patients with FOP have increased levels of BMP4 protein and its mRNA,<sup>34</sup> as well as impairment of the normal negative feedback control of BMP4 by its antagonists such as gremlin and noggin.<sup>35</sup> Transgenic mice expressing BMP4 under control of a nerve-specific enolase promoter exhibit progressive heterotopic ossification but lack the great toe findings of FOP.<sup>36</sup> Overexpression of the secreted BMP4 antagonist noggin can prevent FOP in animal models.<sup>37</sup>

Despite these advances, the genetic mutation responsible for FOP is unknown, and currently there is no molecular diagnostic test. The diagnosis of FOP remains clinical and is entirely reliable. Although other conditions can be associated with malformed toes, no conditions other than FOP are associated with both malformed great toes and episodic soft-tissue swellings in characteristic anatomic locations during childhood. We hope that increased knowledge and awareness regarding FOP among clinicians in all fields will lead to early accurate diagnoses and help prevent the devastating iatrogenic complications that have been the lot of so many patients with FOP. Unfortunately, iatrogenic harm resulting from diagnostic failures for this rare disorder is common worldwide and has shaped the natural history of the disease for most affected individuals. Attention to easily identifiable signs and symptoms of FOP, early in life and long before the appearance of disabling heterotopic ossification, can limit the disability and lifelong harm resulting from diagnostic errors and inappropriate invasive interventions.

#### ACKNOWLEDGMENTS

We gratefully acknowledge the invaluable cooperation of the individuals with FOP and their families who participated in this study. We thank the IFOPA for its support and cooperation, Patricia Delai, MD (São Paulo, Brazil), for helping her patients complete the questionnaire, Matthew Horick for technical assistance, Francis Poulain, MD (Davis, CA), for translating the questionnaire into French, Robert Goldsby, MD (UCSF), for his critical review of the manuscript, and the following for assistance in having questionnaires reach individuals in various countries: Janet Basu and Sam Hawgood, MB, BS (UCSF), Javier Kattan, MD (Santiago, Chile), Hugo Lagercrantz, MD, PhD (Stockholm, Sweden), Isabel Shuster, RN (Montreal, Canada), John Simpson, MB, BS (London, England), Augusto Sola, MD (Atlanta, GA), Hans

Versmold, MD (Berlin, Germany), and R. M. L. Whitlock, MB, BS (Auckland, New Zealand).

#### REFERENCES

- McCarthy BD, Beshansky JR, D'Agostino RB, Selker HP. Missed diagnoses of acute myocardial infarction in the emergency department: results from a multicenter study. *Ann Emerg Med.* 1993;22:579-582
- Pope JH, Aufderheide TP, Ruthazer R, et al. Missed diagnoses of acute cardiac ischemia in the emergency department. *N Engl J Med.* 2000;342:1163-1170
- Connor JM, Evans DAP. Genetic aspects of fibrodysplasia ossificans progressiva. *J Med Genet.* 1982;19:35-39
- Kaplan FS, Tabas JA, Gannon FH, Finkel G, Hahn GV, Zasloff MA. The histopathology of fibrodysplasia ossificans progressiva: an endochondral process. *J Bone Joint Surg Am.* 1993;75:220-230
- Delatycki M, Rogers JG. The genetics of fibrodysplasia ossificans progressiva. *Clin Orthop.* 1998;346:15-18
- Schroeder HW, Zasloff M. The hand and foot malformations in fibrodysplasia ossificans progressiva. *Johns Hopkins Med J.* 1980;147:73-78
- Connor JM, Evans DAP. Fibrodysplasia ossificans progressiva: the clinical features and natural history of 34 patients. *J Bone Joint Surg Br.* 1982;64:76-83
- Cohen RB, Hahn GV, Tabas JA, et al. The natural history of heterotopic ossification in patients who have fibrodysplasia ossificans progressiva. *J Bone Joint Surg Am.* 1993;75:215-219
- Lanchoney TF, Cohen RB, Rocke DM, Zasloff MA, Kaplan FS. Permanent heterotopic ossification at the injection site after diphtheria-tetanus-pertussis immunizations in children who have fibrodysplasia ossificans progressiva. *J Pediatr.* 1995;126:762-764
- Shah PB, Zasloff MA, Drummond D, Kaplan FS. Spinal deformity in patients who have fibrodysplasia ossificans progressiva. *J Bone Joint Surg Am.* 1994;76:1442-1450
- Luchetti W, Cohen RB, Hahn GV, et al. Severe restriction in jaw movement after routine injection of local anesthetic in patients who have fibrodysplasia ossificans progressiva. *Oral Surg Oral Med Oral Pathol Oral Radiol Endod.* 1996;81:21-25
- Scarlett RF, Rocke DM, Kantanie S, Patel JB, Shore EM, Kaplan FS. Influenza-like viral illnesses and flare-ups of fibrodysplasia ossificans progressiva. *Clin Orthop.* 2004;423:275-279
- Kohn LT, Corrigan JM, Donaldson MS, eds. *To Err Is Human: Building a Safer Health System.* Washington, DC: National Academy Press; 2000
- Weingart SN, Wilson RM, Gibberd RW, Harrison B. Epidemiology of medical error. *Br Med J.* 2000;320:774-777
- Bhasale AL, Miller GC, Reid SE, Britt HC. Analysing potential harm in Australian general practice: an incident monitoring study. *Med J Aust.* 1998;169:73-76
- Wilson RM, Runciman WB, Gibberd RW, Harrison BT, Newby L, Hamilton JD. The Quality in Australian Health Care Study. *Med J Aust.* 1995;163:458-471
- Thomas EJ, Studdert DM, Burstin HR, et al. Incidence and types of adverse events and negligent care in Utah and Colorado in 1992. *Med Care.* 2000;38:261-271
- Runciman WB, Webb RK, Helps SC, et al. A comparison of iatrogenic injury studies in Australia and the USA: reviewer behaviour and quality of care. *Int J Qual Health Care.* 2000;12:379-388
- Herndon JH. One more turn of the wrench. *J Bone Joint Surg Am.* 2003;85:2036-2048
- Leape LL, Lawthers AG, Brennan TA, Johnson WG. Preventing medical injury. *Qual Rev Bull.* 1993;8:144-149
- Wilson RM, Harrison BT, Gibberd RW, Hamilton JD. An analysis of the causes of adverse events from the Quality in Australian Health Care Study. *Med J Aust.* 1999;170:411-415
- Brown DL. Analysis of the institutional volume-outcome relations for balloon angioplasty and stenting in the stent era in California. *Am Heart J.* 2003;146:1071-1076
- Phibbs CS, Bronstein JM, Buxton E, Phibbs RH. The effects of patient volume and level of care at the hospital of birth on neonatal mortality. *JAMA.* 1996;276:1054-1059
- Goodney PP, Lucas FL, Birkmeyer JD. Should volume standards for cardiovascular surgery focus only on high-risk patients? *Circulation.* 2003;107:384-387
- de Rijk MC, Launer LJ, Berger K, et al. Prevalence of Parkinson's disease in Europe: a collaborative study of population-based cohorts. *Neurology.* 2000;54(suppl 5):S21-S23



26. Schrag A, Ben-Shlomo Y, Quinn N. How valid is the clinical diagnosis of Parkinson's disease in the community? *J Neurol Neurosurg Psychiatry*. 2002;73:529–534
27. Prashanth LK, Taly AB, Sinha S, Arunodaya GR, Swamt HS. Wilson's disease: diagnostic errors and clinical implications. *J Neurol Neurosurg Psychiatry*. 2004;75:907–909
28. Walshe JM, Yealland M. Wilson's disease: the problem of delayed diagnosis. *J Neurol Neurosurg Psychiatry*. 1992;55:692–696
29. Bates DW, Cohen M, Leape LL, Overhage JM, Shabot MM, Sheridan T. Reducing the frequency of errors in medicine using information technology. *J Am Med Inform Assoc*. 2001;8:299–308
30. Gannon FH, Glaser D, Caron R, Thompson LDR, Shore EM, Kaplan FS. Mast cell involvement in fibrodysplasia ossificans progressiva. *Hum Pathol*. 2001;32:842–848
31. Gannon FH, Kaplan FS, Olmstead E, Finkel GC, Zasloff MA, Shore E. Bone morphogenetic protein 2/4 in early fibromatous lesions of fibrodysplasia ossificans progressiva. *Hum Pathol*. 1997;28:339–343
32. Hegyi L, Gannon FH, Glaser DL, Shore EM, Kaplan FS, Shanahan CM. Stromal cells of fibrodysplasia ossificans progressiva lesions express smooth cell lineage markers and the osteogenic transcription factor Runx2/Cbfa-1: clues to a vascular origin of heterotopic ossification? *J Pathol*. 2003;201:141–148
33. Serrano de la Pena L, Billings PC, Fiori JL, Ahn J, Kaplan FS, Shore EM. Fibrodysplasia ossificans progressiva, a disorder of ectopic osteogenesis, misregulates cell surface expression and trafficking of BMPRIA. *J Bone Miner Res*. 2005;20:1168–1176
34. Shafritz AB, Shore EM, Gannon FH, et al. Overexpression of an osteogenic morphogen in fibrodysplasia ossificans progressiva. *N Engl J Med*. 1996;335:555–561
35. Ahn J, Serrano de la Pena L, Shore EM, Kaplan FS. Paresis of a bone morphogenetic protein-antagonist response in a genetic disorder of heterotopic skeletogenesis. *J Bone Joint Surg Am*. 2003;85:667–674
36. Kan L, Hu M, Gomes WA, Kessler JA. Transgenic mice overexpressing BMP4 develop a fibrodysplasia ossificans progressiva (FOP)-like phenotype. *Am J Pathol*. 2004;165:1107–1115
37. Glaser DL, Economides AN, Wang L, et al. In vivo somatic cell gene transfer of an engineered Noggin mutein prevents BMP4-induced heterotopic ossification. *J Bone Joint Surg Am*. 2003;85:2332–2342

**Iatrogenic Harm Caused by Diagnostic Errors in Fibrodysplasia Ossificans  
Progressiva**

Joseph A. Kitterman, Sharon Kantanie, David M. Rocke and Frederick S. Kaplan  
*Pediatrics* published online Oct 17, 2005;  
DOI: 10.1542/peds.2005-0469

**This information is current as of October 24, 2005**

**Updated Information  
& Services**

including high-resolution figures, can be found at:  
<http://www.pediatrics.org/cgi/content/full/peds.2005-0469v1>

**References**

This article cites 35 articles, 18 of which you can access for free at:  
<http://www.pediatrics.org/cgi/content/full/peds.2005-0469v1#BIBL>

**Subspecialty Collections**

This article, along with others on similar topics, appears in the following collection(s):  
**Musculoskeletal System**  
[http://www.pediatrics.org/cgi/collection/musculoskeletal\\_system](http://www.pediatrics.org/cgi/collection/musculoskeletal_system)

**Permissions & Licensing**

Information about reproducing this article in parts (figures, tables) or in its entirety can be found online at:  
<http://www.pediatrics.org/misc/Permissions.shtml>

**Reprints**

Information about ordering reprints can be found online:  
<http://www.pediatrics.org/misc/reprints.shtml>

American Academy of Pediatrics

DEDICATED TO THE HEALTH OF ALL CHILDREN™

